



**TITLE: INTEGRATING HOMEOPATHY IN THE MANAGEMENT OF RINGWORM: A CASE STUDY”**

**ABOUT AUTHOR:**

**Dr. Suman Chaudhary MD (Hom) Ph.D Scholar,**  
HOD, Associate Professor, Department Of Pathology  
Smt. A. J. Savala Homoeopathic Medical College &  
Research Institute, Mehsana.


Email Id: [dr.suman1989@gmail.com](mailto:dr.suman1989@gmail.com)



**ASSIST BY,**

**Bharat Chaudhary BHMS IV Year**  
AJSHMC Mehsana, Gujarat

Email id: [thebharatchaudhary@gmail.com](mailto:thebharatchaudhary@gmail.com)



**ABSTRACT:** Ringworm is an itchy, contagious fungal infection that causes a ring-shaped pattern on skin. Fungal infections are common in day-to-day practice. Numerous systemic and topical anti-fungal & steroid are treatments currently in use; nevertheless, they are known to have significant side effects and high rates of treatment failure. Because fungal infections have a higher likelihood of recurrence and can cause more widespread illnesses if left untreated, they present a significant challenge. In this article, a case of Ringworm successfully cured by homoeopathy has been reported.

**KEY WORDS:** Ringworm, homoeopathy



## **INTRODUCTION:**

Dermatophytes are fungi that infect skin, hair, and nails and include members of the genera Trichophyton, Microsporum and Epidermophyton. It is designated as tinea followed by the name of the affected part <sup>[1]</sup>.

Dermatophyte infection of the skin is often called ringworm. Dermatophytes occur worldwide and infections with these organisms are extremely common. Dermatophytes are transmitted from person-to-person through contact and fomites, and the infections are more commonly observed in males than in females. The characteristic ring shape of cutaneous lesion is the result of dermatophyte's outward growth in a centrifugal pattern in the stratum corneum <sup>[2]</sup>. The tinea infection may reach epidemic proportion in geographical areas with higher humidity, high population density and poorhygienic conditions <sup>[3]</sup>.

Homeopathy has a broad scope in treatment of ringworm. Homeopathic similimum remedy not only stops recurrence of attacks but also improve mental state of patient which is not possible in treatment with modern medicines.

## **CASE REPORT**

Name: XYZ

Age/Sex: 24/Male

Occupation: Civil engineer

Marital status: unmarried

Address: Tharad

Date:12/05/24

### **CHIEF COMPLAIN:**

A red, scaly, itchy ring-shaped area, typically on the buttocks, trunk, arms and legs with itching and burning since 6 months.

Patient done antifungal allopathic course but eruption reappear periodically.

Modalities:

Aggravation- Night

Amelioration- uncovering



PAST HISTORY:

History of Scabies before 3 months.

FAMILY HISTORY:

No significant illness.

PERSONAL HISTORY:

- Appetite: Decreased, for 2 years. Though he eats still feel that he does not have enough energy
- Thirst: Increased, 7 to 8 lit./day
- Desire /Aversion: Not specific
- Urine: Normal
- Stool: Regular
- Sleep: Sound
- Habit: Tea 2 times a day.
- Thermal:Hot

MENTAL GENERAL:

The patient said that he gets angry easily over small things. And when anger comes, the voice becomes louder. Relationships deteriorate quickly. Then I regret it and try not to get angry soon. Also I can't refuse anyone, if someone asks for money, I will give it even if I don't have it, I want to learn say to "no"

**TOTALITY OF SYMPTOMS:**

1. Skin- itching
2. Skin-Burning
3. Skin- Eruption- Circinate
4. Skin-Eruption – Ringworm
5. Mind- Anger- Trifles at
6. Mind- Anger - alternating with repentance;quick
7. Mind-  
Hurry
8. Mind- Yielding disposition

MIND			
1 MIND - ANGER - alternating with - repentance; quick			⊗
2 MIND - ANGER - trifles; at			⊗
3 MIND - HURRY			⊗
4 MIND - YIELDING disposition			⊗
SKIN			
5 SKIN - ERUPTIONS - burning			⊗
6 SKIN - ERUPTIONS - herpetic - circinate			⊗
7 SKIN - ERUPTIONS - itching			⊗
8 SKIN - ERUPTIONS - ringworm			⊗
Remedies	ΣSym	ΣDeg	Symptoms
nat-m.	7	15	2, 3, 4, 5, 6, 7, 8
sulph.	7	14	1, 2, 3, 5, 6, 7, 8
sep.	7	13	2, 3, 4, 5, 6, 7, 8
thuj.	7	12	2, 3, 4, 5, 6, 7, 8
dulc.	7	10	2, 3, 4, 5, 6, 7, 8
sil.	6	11	2, 3, 4, 5, 7, 8
hep.	6	10	2, 3, 5, 6, 7, 8

Table 1. Repertorization

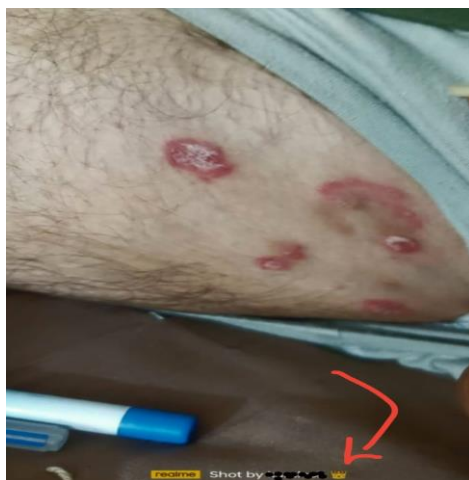

Figure 01 Retrospective confirmation

PRESCRIPTION:-

Sulphur 200 Single dose SL

BD for 15 days

FOLLOW UP:-

**28/05/24 –**

- Eruption on skin increased suddenly due to suppression of eruption by conventional medical treatment, but patient mentally feel better.
- SL continue for 15 days

**17/06/2024**

- Itching disappear, eruption also decreased Sulphur 200 Single dose
- SL bd for 15 days

**30/06/2024**

- Skin eruption becoming gradually fade. Sulphur 1M Single dose
- SL bd for 30 days

**27/07/2024**

- Eruption almost disappear, also he learn to say “NO”.
- SL bd for 30 days

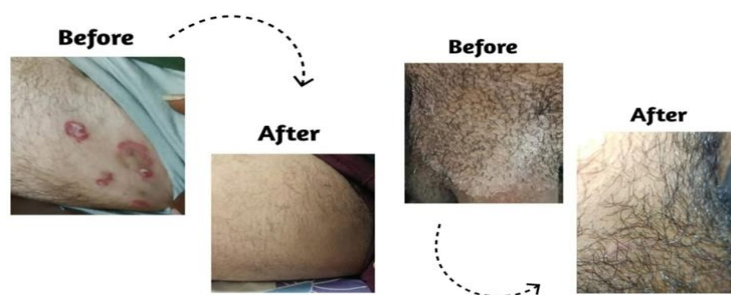

Figure 02 Before and after treatment



## **CONCLUSION:**

Remedies going parallel with one- or two-point difference, then the final selection of is physician's decision as per his finer unprejudiced observation and Present totality of symptom portraying the ultimate picture and knowledge of Materia Medica.

## **REFERENCES:**

1. Khanna Neena, Singh Sourabh. 6th ed. Japee Brother Medical Publisher Ltd; 2015. Bhutani color atlas of Dermatology, Ch.7-dermatitis and eczema; p. 115. [[Google Scholar](#)]
2. Kasper Denis L., Fauci A.S., Hauser S.L., Longo D., Jameson J.L.J., Loscalzo J. 19th ed. Mc Graw Hill Education; Newyork: 2015. Harrisons principles of internal medicine, Volume 2, Ch. 243; p. 1357. [[Google Scholar](#)]
3. Weitzman Irene, Summerbell Richard C. The dermatophytes. *Clin. Microbiol. Rev.* 1995 April;8(2):240–259. [[PMC free article](#)] [[PubMed](#)][[Google Scholar](#)]